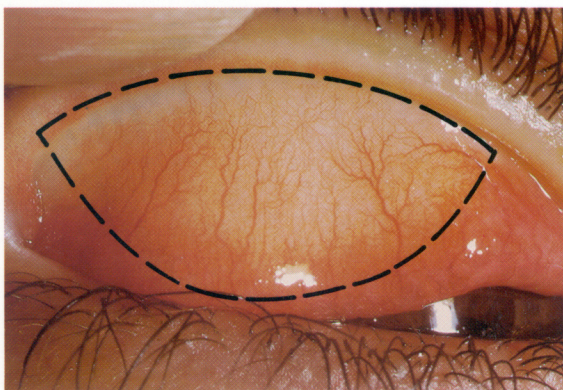


# TRACHOMA GRADING CARD

- Each eye must be examined and assessed separately.
- Use binocular loupes (x 2.5) and adequate lighting (either daylight or a torch).
- Signs must be clearly seen in order to be considered present.

The eyelids and cornea are observed first for inturned eyelashes and any corneal opacity. The upper eyelid is then turned over (everted) to examine the conjunctiva over the stiffer part of the upper lid (tarsal conjunctiva).

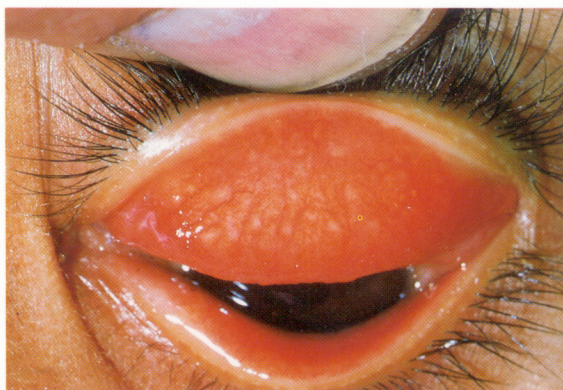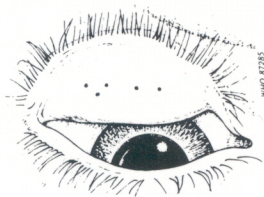
The normal conjunctiva is pink, smooth, thin and transparent. Over the whole area of the tarsal conjunctiva there are normally large deep-lying blood vessels that run vertically.



*Normal tarsal conjunctiva (x 2 magnification).  
The dotted line shows the area to be examined.*

**TRACHOMATOUS INFLAMMATION – FOLLICULAR (TF):** the presence of five or more follicles in the upper tarsal conjunctiva.

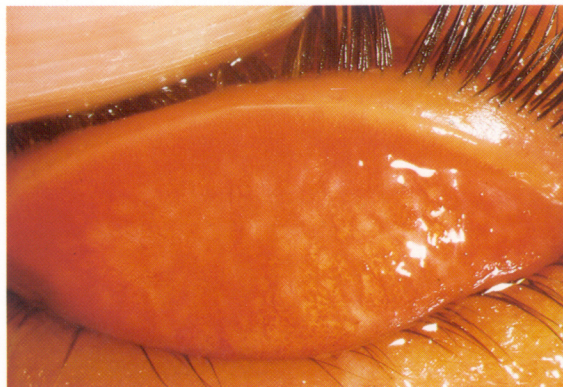
Follicles are round swellings that are paler than the surrounding conjunctiva, appearing white, grey or yellow. Follicles must be at least 0.5mm in diameter, i.e., at least as large as the dots shown below, to be considered.



*Trachomatous inflammation – follicular (TF).*

**TRACHOMATOUS INFLAMMATION – INTENSE (TI):** pronounced inflammatory thickening of the tarsal conjunctiva that obscures more than half of the normal deep tarsal vessels.

The tarsal conjunctiva appears red, rough and thickened. There are usually numerous follicles, which may be partially or totally covered by the thickened conjunctiva.

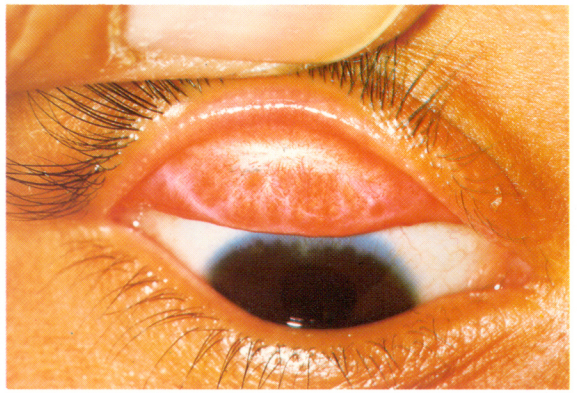


*Trachomatous inflammation – follicular and intense (TF + TI).*

**TRACHOMATOUS SCARRING**

**(TS):** the presence of scarring in the tarsal conjunctiva.

Scars are easily visible as white lines, bands, or sheets in the tarsal conjunctiva. They are glistening and fibrous in appearance. Scarring, especially diffuse fibrosis, may obscure the tarsal blood vessels.

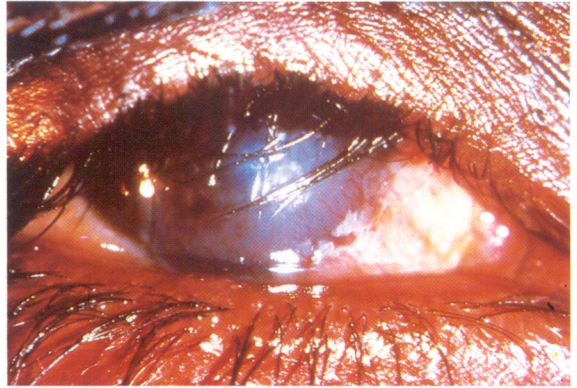


*Trachomatous scarring (TS)*

**TRACHOMATOUS TRICHIASIS**

**(TT):** at least one eyelash rubs on the eyeball.

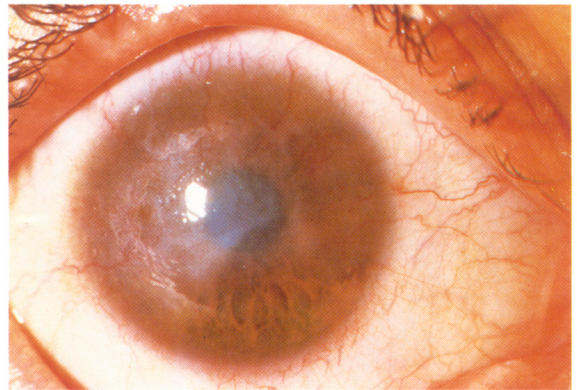
Evidence of recent removal of inturned eyelashes should also be graded as trichiasis.



*Trachomatous trichiasis (TT)*

**CORNEAL OPACITY (CO):** easily visible corneal opacity over the pupil.

The pupil margin is blurred viewed through the opacity. Such corneal opacities cause significant visual impairment (less than 6/18 or 0.3 vision), and therefore visual acuity should be measured if possible.



*Corneal opacity (CO)*

**TF:– give topical treatment (e.g. tetracycline 1%).**  
**TI:– give topical and consider systemic treatment.**  
**TT:– refer for eyelid surgery.**



**WORLD HEALTH ORGANIZATION  
PREVENTION OF BLINDNESS AND DEAFNESS**

